

PATIENT PRESENTING CLINICAL SIGNS

Dillon Datesman History: Possible arrhythmia, history of heart disease. ECG showed a mild sinus tachycardia (HR 220 bpm).

SPECIES

Feline

ECHOCARDIOGRAPHIC FINDINGS

2D, M-mode, and Doppler study.

BREED

DSH

Left atrial size is normal. The mitral valve leaflets are mildly thickened, and a mild jet of eccentric mitral regurgitation is present. Left ventricular dimensions are normal. Left ventricular systolic function is hyperdynamic. The aorta and aortic valve are normal. Right atrial and right ventricular dimensions are normal. The tricuspid valve leaflets are mildly thickened, and a mild jet of tricuspid regurgitation is present. The pulmonary artery and pulmonic valve are normal. No shunting lesions are visualized. No pericardial effusion or cardiac masses are seen.

SEX

Male Neutered

AGE

11 years

LA - 14.1 mm
LA/Ao - 1.31
IVSd - 3.9 mm
LVPWd - 3.8 mm
LVIDd - 14.9 mm
LVIDs - 7.5 mm
FS - 49.7%
RA - 10.3 mm
LVOT - 1.38 m/s
RVOT - 1.26 m/s

WEIGHT

15.8#

INTERPRETED BY

Keith Blass, DVM,
MS, DACVIM

ASSESSMENT/RECOMMENDATIONS

Normal echocardiogram and ECG

IMAGING PERFORMED BY

Rebekah Jakum, CVT
ARDMS/RVT

Dillon's echocardiogram demonstrates no evidence of structural heart disease. While it's possible that he could have suffered from cardiac dysfunction in the past, any abnormalities that could have been present would appear to have resolved, as no abnormalities are appreciated in today's exam. As such, no reason for Dillon's abnormal walking this morning is appreciated in the image set.

HOSPITAL NAME

Pocono Peak VC

No abnormalities are seen in Dillon's ECG, though it's possible that he could be experiencing an intermittent arrhythmia that was not captured in the recording.

No therapy is recommended based on these exams.

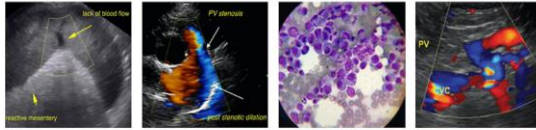
REFERRING VET

Dr. Covle

A Holter monitor can be considered to evaluate for an intermittent arrhythmia. A recheck echocardiogram is recommended if new physical exam and/or clinical abnormalities suggestive of cardiac dysfunction develop.

DATE

1.26.2022



PATIENT

Dillon Datesman

SPECIES

Feline

BREED

DSH

SEX

Male Neutered

AGE

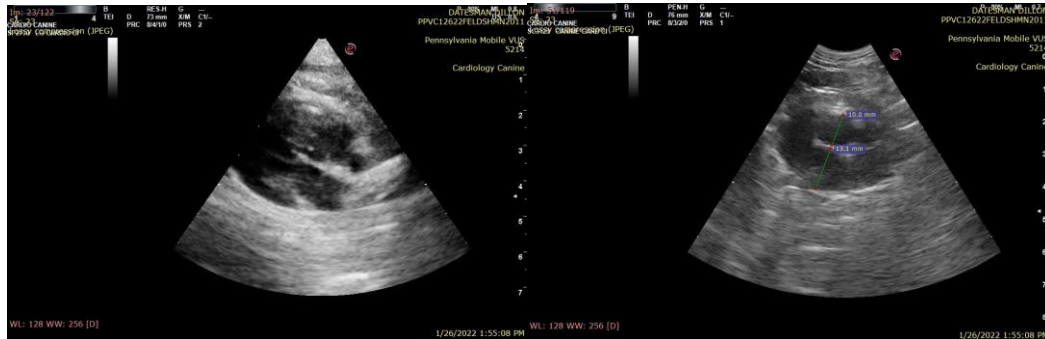11 years

WEIGHT

15.8#

INTERPRETED BY

Keith Blass, DVM,
MS, DACVIM



The information and recommendations provided are based on the images presented by the referring veterinarian. No evaluation can be communicated regarding pathology that was not visible in the image/video clips provided.

Thank you for this referral. If the clinical or image interpretation does not parallel your findings or if I can be of any further assistance please contact me.

Keith Blass, DVM, MS, DACVIM (Cardiology)

KeithBlass@gmail.com

631-804-5754

IMAGING PERFORMED BY

Rebekah Jakum, CVT
ARDMS/RVT

HOSPITAL NAME

Pocono Peak VC

REFERRING VET

Dr. Covle

DATE

1.26.2022